

## Review article

## Hypersensitivity reactions to anticoagulant drugs: diagnosis and management options

Anticoagulants, including heparins, coumarins, hirudins, and some of the previously used plasma volume expanders, belong to the most widely used drugs. Hypersensitivity reactions from these agents are uncommon. However, they may have a considerable impact on patient safety and treatment decisions. Therefore, early diagnosis of potentially life-threatening adverse events and identification of alternatives is clinically important. This review contains an update on current knowledge about hypersensitivity reactions caused by the different anticoagulants. In addition, it discusses pathophysiologic mechanisms, diagnostic possibilities, and management options. The most common hypersensitivity reactions are erythematous plaques, occurring with a delay after subcutaneous application of heparins. Seldom they turn into maculopapular exanthema. Other hypersensitivity reactions are rare but may be life-threatening, e.g. skin necrosis because of heparin-induced thrombocytopenia. Skin and provocation tests with immediate and late readings are the most reliable diagnostic tools for heparin- or hirudin-induced urticaria/anaphylaxis or heparin-induced delayed plaques. If necrosis from heparins or coumarins is suspected, skin tests are contraindicated. In anaphylactic reactions caused by dextrans or hydroxyethyl starch skin tests are useless. Most *in vitro* tests have a low sensitivity and are not generally available. Therefore, in some anticoagulant-associated hypersensitivity reactions detailed allergologic investigation may help to identify safe treatment alternatives. However, several tests may be needed, and the procedures are usually time-consuming.

**A. J. Bircher<sup>1,2</sup>, T. Harr<sup>1</sup>,  
L. Hohenstein<sup>2</sup>, D. A. Tsakiris<sup>3</sup>**

<sup>1</sup>Allergy Unit, University Hospital, Basel;  
<sup>2</sup>Department of Dermatology, University Hospital, Basel; <sup>3</sup>Division of Hematology, University Hospital, Basel, Switzerland

Key words: allergy; anticoagulants; diagnosis; hypersensitivity reactions; pathogenesis.

Andreas J. Bircher MD  
Allergy Unit  
Department of Dermatology  
Petersgraben 4  
4031 Basel  
Switzerland

Accepted for publication 12 July 2006

Anticoagulants belong to the most widely used drugs. They include a variety of pharmacologic agents, including heparins, coumarins, direct thrombin inhibitors, antiplatelet drugs, and currently, for this indication, no longer used plasma volume expanders, such as dextrans and hydroxyethyl starch (HES; Table 1). These agents have different chemical structures and different modes of action (1). All of them may provoke hypersensitivity reactions based on various pathogenetic pathways. These have different clinical manifestations and degrees of severity. This review will focus on the discussion of hypersensitivity reactions to heparins, hirudins, and coumarins.

## Heparins

Heparins are important anticoagulants, used in the prophylaxis and treatment of thromboembolic disorders. Chemically they are sulfated carbohydrates of different molecular weights. Today, this chemical group includes a vast spectrum of agents from unfractionated heparin (UFH), low-molecular weight heparins (LMWH), heparinoids to the pentasaccharides (Table 1). The most common adverse event is hemorrhage; late side effects

include telogen effluvium, alopecia, osteoporosis, lipodystrophy, and a reversible increase of liver enzymes (2, 3).

Heparin may cause all types of allergic reactions, particularly cell-mediated type IV and antibody-mediated type II reactions. Very rarely also immediate type I reactions occur. Heparin is a sulfated proteoglycane (mucopolysaccharide) with strong protein-binding capacity because of its highly negative charge. Therefore, its action can also be immediately inhibited by the positively charged protamine, a derivative of salmon sperm. In allergic reactions this negative charge seems to play an important pathogenetic role, as the heparin molecule adheres to human proteins. However, the allergen or allergens causing the different hypersensitivity reactions are still unknown. Cross-reactivity between unfractionated and the different LMWHs and heparinoids has been observed.

Although heparins are widely used, allergic reactions from this substance group are rare. The most common reactions involve cell-mediated hypersensitivity with clinical manifestations of erythematous plaques and sometimes maculopapular exanthemas. The most

Table 1. Anticoagulants

Unfractionated heparins	
	Heparin calcium (Calciparine <sup>®</sup> )
	Heparin sodium (Liquemin <sup>®</sup> )
Low-molecular weight heparins	
	Enoxaparin sodium (Clexane <sup>®</sup> )
	Dalteparin sodium (Fragmin <sup>®</sup> )
	Nadroparin calcium (Fraxiparine <sup>®</sup> )
	Certoparin sodium (Sandoparin <sup>®</sup> )
Semisynthetic heparinoid	
	Danaparoid sodium (Orgaran <sup>®</sup> )
Synthetic pentasaccharide	
	Fondaparinux sodium (Arixtra <sup>®</sup> )
Direct thrombin inhibitors	
Hirudins, recombinant	
	Lepirudin (Refludan <sup>®</sup> )
	Desirudin (Revasc <sup>®</sup> )
Synthetic inhibitors	
	Argatroban (Acova <sup>®</sup> )
	(Xi)-Melagatran (Exanta <sup>®</sup> )*
Coumarins	
	Coumadin (Warfarin <sup>®</sup> )
	Phenprocoumon (Marcoumar <sup>®</sup> )
	Acenocoumarol (Sintrom <sup>®</sup> )
Volume expanders	
	Dextran
	Hydroxyethyl starch

\*Withdrawn due to hepatotoxicity.

dangerous hypersensitivity reaction is heparin-induced thrombocytopenia (HIT II), a type II immunoglobulin (Ig)G antibody-mediated reaction. Heparin-induced thrombocytopenia II and anaphylaxis are relatively rare (4).

### Cell-mediated hypersensitivity to heparins

After a sensitization or induction period of at least 7–10 days, but more often after weeks to months, patients develop pruritic erythematous lesions at the injection sites. The latency period in previously sensitized individuals lasts typically from 1 to several days. Manifestations include erythematous plaques at the injection sites (Fig. 1). These are sometimes followed by formation of vesicles and bullae. Pruritus may be severe and hemorrhage because of the anticoagulant effect may be seen. Upon continuing subcutaneous or also occasionally after intravenous administration, maculopapular exanthemas or localized flare-ups at locations of previous reaction may be observed in sensitized individuals (5–7). It has not been investigated whether or not the anticoagulant effect of heparin is impaired in patients with delayed hypersensitivity. Plaques are more common after application of UFH and LMWH. They occur seldom with danaparoid and the pentasaccharide fondaparinux (8).

The main differential diagnoses include local hematoma, infections, such as erysipelas, contact dermatitis

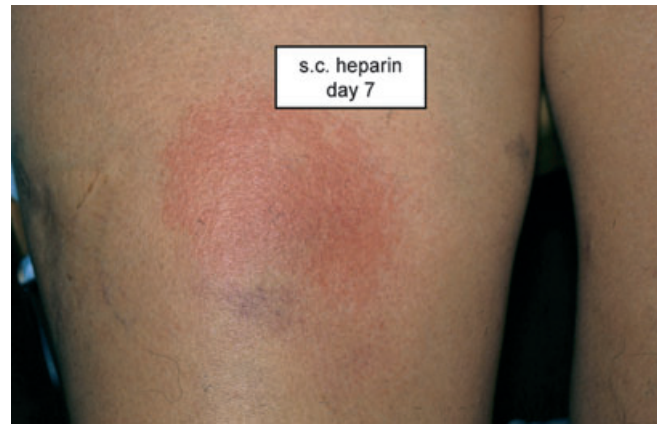

Figure 1. Heparin-induced delayed erythematous plaque at day 7 after subcutaneous injection.

(e.g. from disinfectants), and particularly heparin-induced skin necrosis, i.e. the cutaneous manifestation of the initial phase of HIT II. The latter presents with hemorrhagic lesions and skin necrosis at injection sites, also rarely at distant locations. It can affect internal organs as well and may be lethal (9–11).

Histologic findings show a dense lympho-histiocytic infiltrate with spongiosis of the epidermis, representing a contact dermatitis-type reaction. Immune histochemistry reveals predominant CD4 and few CD8-positive T cells, indicating a cell-mediated hypersensitivity reaction (6, 12).

Risk factors appear to be female gender, obesity, and repetitive or long-lasting treatment, e.g. during pregnancy. The vast majority of the several hundred reported published cases are females. Therefore, hormonal factors, longer persistence of heparins in subcutaneous adipose tissue or a relationship to the lipase activity of heparins have been proposed to explain this striking gender difference (7, 12, 13).

Generalized maculopapular, sometimes bullous and febrile exanthemas (DRESS), Lyell syndrome, and flexural exanthemas (so-called Baboon Syndrome or SDRIFE; 14) have rarely been reported (6).

### Immediate hypersensitivity to heparins

Palmoplantar pruritus after subcutaneous and intravenous application of heparins has been observed, possibly representing an early sign of immediate type hypersensitivity. Reported symptoms include pruritus, urticaria, conjunctivitis, rhinitis, bronchial asthma (6, 15), and anaphylaxis (15). These reactions were formerly attributed to preservatives and contaminants, such as proteins from animal origin (7, 15). Today immediate type reactions to heparin compounds, probably involving an IgE-mediated pathomechanism, seem to be very rare (16). Recently, an immediate hypersensitivity to dalteparin was

observed in a female patient. Cross-reactivity to other LMWH preparations and positive skin tests were documented. Unfractionated heparin, fondaparinux and lepirudin were skin test-negative, although the patient had also been previously exposed to the two former substances. They were tolerated upon re-exposure (16).

### Eosinophilia

Isolated reactive peripheral hypereosinophilia after subcutaneous heparin application has been reported. Possibly an activation of CD4 as well as interleukin (IL)-3 and IL-5 secretion can stimulate formation and activation of eosinophils (17, 18).

### Heparin necrosis and thrombocytopenia

Heparin necrosis (Fig. 2) looks clinically very similar to coumarin necrosis (Fig. 3). It may initially be confounded with plaques in cell-mediated hypersensitivity (9, 17). Heparin necrosis is the cutaneous manifestation of the severe form of HIT II. Heparin-induced thrombocytopenia II occurs in about 1–4% of patients treated with UF-heparin. Surgical patients are at highest risk. A lower risk is present during treatment with LMWH as well as in pediatric patients. Clinical definition of HIT II is an acquired platelet count of < 100 000 or a 50% decrease from baseline values, occurring 5–10 days after initiation of heparin therapy in the absence of another etiology. This means that some patients with HIT II have platelet counts still within the normal range, but lower than the preheparin exposure baseline (19). Heparin-induced thrombocytopenia II begins typically after 6–8 days of treatment. It is characterized by a sudden decrease of

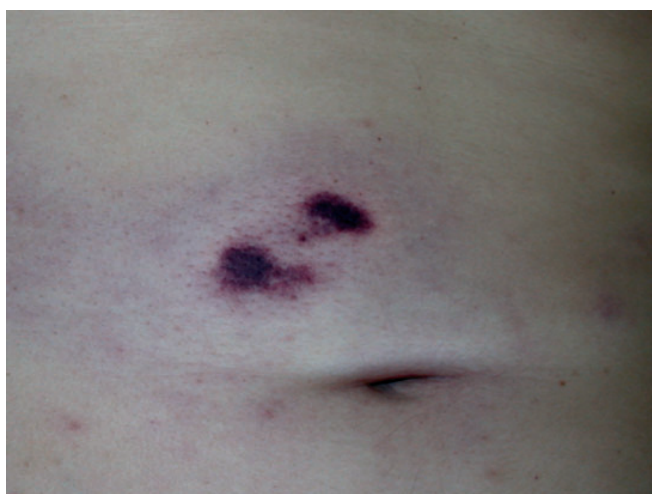

Figure 2. Heparin-induced skin necrosis in heparin-induced thrombocytopenia II.

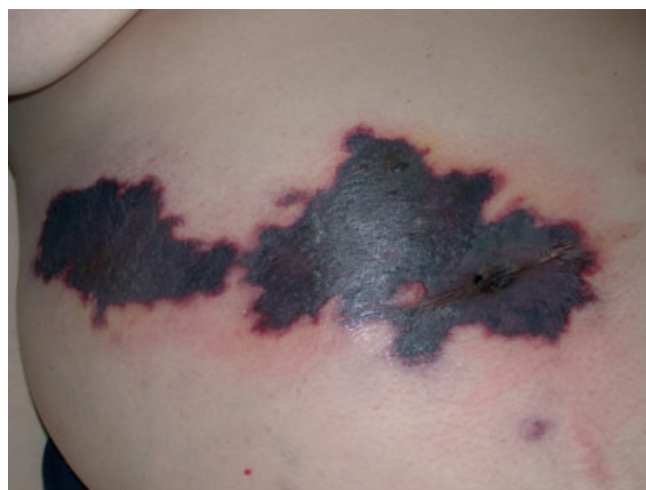

Figure 3. Coumarin-associated skin necrosis in a patient with protein C deficiency.

platelets. Thromboembolic events occur in more than 50% of patients. Low-molecular weight heparin-induced skin necrosis may occur as part of HIT syndrome, but other factors, such as local trauma, may also be involved (20). Disseminated thrombosis of vessels in the skin and in other organs is called white clot syndrome. Clinically hemorrhagic, sometimes bullous lesions and plaques with rapid evolution toward necrosis are present. Rarely sclerodermiform lesions have been described. Lesions may be present at the injection site or at distant locations and may cause thrombosis in organs, such as the central nervous system and the kidneys.

Almost all individuals with HIT II have antibodies to heparin–platelet factor 4 (PF4) complexes in their plasma at the time the disease develops. PF4 is a platelet-specific CXC chemokine, released in high concentrations at sites of platelet activation. Heparin–PF4 complexes form through an interaction between the highly sulfated anionic heparin and a circumferential band of lysine and arginine residues on PF4. Binding of PF4 to polyanions appears to expose new antigenic epitopes that lead to antibody formation. This phenomenon is not heparin-specific. Other negatively charged polyanions, such as glycosaminoglycans, can also express such epitopes. Although all major classes of antibodies have been detected, it appears that patients with high IgG titers are at greatest risk of developing clinical thrombotic disease, as IgM- or IgA-Ab cannot activate platelets via Fc-receptors as IgG-Ab do. Antiheparin–PF4 antibodies also appear to be more prevalent among individuals undergoing cardiac bypass surgery, a situation in which high doses of heparin are used in the setting of intense platelet activation (19, 21). It is not clear whether antibodies against some PF4-related chemokines, such as neutrophil-activating peptide-2 (NAP-2) or IL-8 are clinically relevant. Such antibodies have been found in some patients with thrombotic syndromes equivalent to

HIT II, but were not detected by the conventional anti-PF4 assays (22).

As HIT II causes thromboembolic events with high morbidity and mortality, all heparins should be immediately withheld because all UFH and LMWH cross-react with HIT II antibodies. Therefore, patients should be treated with an alternative anticoagulant without cross-reactivity (23). The two direct thrombin inhibitors, hirudin (lepirudin) and argatroban as well as the heparinoid danaparoid are currently recommended. Danaparoid has the most extensive data for this indication in the literature (24). However, danaparoid can be partially cross-reactive *in vitro* (21). Although *in vitro* cross-reactivity can be found in up to 7% of HIT II patients, it does not seem to be clinically significant in contrast to UFH or LMWH (24). Also fondaparinux seems to be safe, as it does not cross-react with serum from patients with documented HIT II (25), but no extensive clinical data on the use of fondaparinux in HIT II patients are available yet.

### Hirudins

Hirudin is a protein derived from the leech *Hirudo medicinalis*, which specifically inhibits thrombin. It can be administered subcutaneously and intravenously. Its half-life is approximately 60 min. There is no specific inhibitor, such as protamine for heparin. Two recombinant hirudins are approved in the European Union: desirudin (Revasc<sup>®</sup>; Aventis, Frankfurt, Germany) and lepirudin (Refludan<sup>®</sup>; Schering, Berlin, Germany; 26). Desirudin is approved for thrombosis prophylaxis following orthopedic hip-replacement surgery and lepirudin for anticoagulation in patients with HIT II and thromboembolic complications. The compounds differ from each other only in their N-termini: desirudin possesses a valine–valine and lepirudin a leucine–threonine sequence. Otherwise desirudin and lepirudin are very similar, with molecular weights of 6.96 kDa and 6.98 kDa, respectively. Because of their completely different chemical structure compared with heparins there is no cross-reactivity to heparins. Therefore, hirudins have been successfully used in patients with HIT II and in patients with cell-mediated reactions to heparins.

### Immediate hypersensitivity reactions to hirudin

In a recent postmarketing surveillance of lepirudin in 35 000 patients, the risk of anaphylaxis was 0.015% (five of 32 500) on first exposure and 0.16% (four of 2500) in re-exposed patients (26, 27). All reactions occurred within minutes in these nine patients with severe anaphylaxis after intravenous lepirudin application. There were four fatal outcomes (three acute cardiorespiratory arrests, one hypotension-induced myocardial infarction). In these

four cases, a previous (1–12 weeks) uneventful treatment course with lepirudin was identified. A 10th patient with anaphylaxis had high-titer IgG-antilepirudin antibodies (26, 27). Three patients who had only mild skin reactions (urticaria and angioedema) were also observed. One participant of pharmacokinetic studies developed urticaria upon subcutaneous re-exposure with recombinant hirudin. Hirudin-specific IgG antibodies could be measured. They were consumed during the reaction and peaked 48 h later (28).

### Delayed reactions to hirudin

There are two published cases of patients with localized delayed reactions. The first had eczematous plaques with a positive lymphocyte transformation test (29), and the second had a granulomatous reaction (30). One female patient with a delayed reaction to certoparin produced an Arthus-like phenomenon after intradermal lepirudin application (31).

Coumarin derivatives (warfarin, phenprocoumon, acenocoumarol)

Several adverse skin manifestations associated with the use of oral anticoagulants, ranging from ecchymoses and purpura, hemorrhagic necrosis, maculopapular, vesicular, and urticarial eruptions to purple toes are known (32, 33). The different compounds (Table 1) vary particularly with regard to dosage and their pharmacologic properties.

### Coumarin necrosis

Coumarin-induced skin necrosis was first described in 1943. It is a rare complication with a prevalence of 0.01–0.1%. It manifests itself with a sudden, localized painful skin lesion. Initially, it is erythematous or hemorrhagic and subsequently becomes bullous, eventually culminating in gangrenous necrosis (Fig. 3). It develops mainly in obese women older than 50 years who have been treated for thrombophlebitis or pulmonary embolism. There seems to be a marked predilection for areas with increased subcutaneous fat, such as breasts, thighs, and buttocks. Differential diagnosis between coumarin-induced skin necrosis and necrotizing fasciitis, venous gangrene, and other causes of skin necrosis may be difficult. The skin lesions may also be confused with other dermatologic entities. The complication typically occurs during the first few days of coumarin therapy, often in association with the administration of a large initial loading dose of the drug (32, 33).

The pathophysiology of coumarin-induced skin necrosis depends on the natural, vitamin K-dependent proteins C and S, normally serving as natural coagulation inhibitors. These proteins have a short half-life of 6–8 h and vitamin K antagonists block their synthesis, resulting in a

rapid decrease. Other procoagulant proteins, such as coagulation factors II, IX and X with considerably longer half-lives, remain active for a longer time in adequate levels, ensuring efficient hemostasis (10, 11). This results in a relative hypercoagulable state ending in thrombotic complications in the microvasculature of the skin with subsequent necrosis. Skin microvasculature is particularly affected because of its anatomical lack of sufficient collateral blood supply. Later, postnecrotic hemorrhage may be observed.

Patients with primary proteins C and S deficiency or those with anticardiolipin syndrome are at greater risk for developing necrosis. Replacement therapy with recombinant protein C concentrate appears to block progression of the lesions and enhances healing (32, 33). Alternatively, longer overlapping periods with heparins during initiation of coumarin administration ensure a complication- and necrosis-free treatment.

### Other hypersensitivity reactions from coumarins

Maculopapular exanthemas from coumarins are very rare. Only few cases have been described (10, 34–37). One patient reacted to three different coumarins (35), another patient had a positive rechallenge (38). Exanthematous reactions, such as urticaria and bullous lesions, are exceptional.

### Dextran and hydroxyethyl starch

Dextran and HES were used frequently in the past, mainly not only as plasma volume replacement, but also for perioperative anticoagulation. Just like other volume expanders they may elicit anaphylactic reactions (39). Their use has been restricted, and they are no longer used as anticoagulants. Hydroxyethyl starch may also cause delayed long-lasting pruritus.

### Hypersensitivity from dextrans

Anaphylactoid reactions to dextrans were frequent in former years. In a survey of anaphylactic reactions reported in Sweden between 1972 and 1995, 1338 reports concerned reactions with at least a possible causal relation to the administered medication (40). In a survey of 201 reported drugs suspected of causing hypersensitivity reaction dextrans were most common (418 reports), followed by X-ray contrast media (161 reports), and antibiotics (153 reports). Dextrans were considered to be responsible for 59% of the 51 fatalities, followed by radio contrast media (20%). An epidemiologic survey of anaphylaxis in the Netherlands showed that dextrans were among the most common drugs provoking anaphylaxis (41). The reported rate of dextran-related anaphylactic reactions, shock and fatal cases was 128 101 and

21 per million bottles, respectively. This rate decreased to 10.3, 9.8, and 0.4 per million bottles after the introduction of preventive treatment by hapten inhibition with low-molecular dextran 1 (Promit<sup>®</sup>; Pharmacia, Uppsala, Sweden) in 1983 (40). Nevertheless, severe shocks have been observed (42) despite this treatment (43). In the meantime, it has been withdrawn from the market.

In the pathogenesis of this immune complex (type III) anaphylaxis, dextran-reactive IgG, particularly IgG2, IgG3, IgG4, and IgG1, plays a central role. In patients with severe reactions high IgA and IgM titers were also found (44, 45). The highest IgG levels were found in patients with lethal outcome. Nonreactors had much lower levels of antibodies. In neither groups IgD or IgE was found. Apparently IgG, particularly IgG2, plays a critical pathogenic role in the induction of the most severe dextran-associated reactions (45).

### Hypersensitivity from hydroxyethyl starch

Pruritus is increasingly recognized as a common major adverse effect of HES administration (46). Usually several weeks elapse between HES exposure and the onset of pruritus. It is often severe and long-lasting (persistence up to 24 months), and refractory to treatment. Most often it is dose-dependent, although it can be provoked by relatively low doses. The widespread and sometimes massive tissue deposition of HES is the pathophysiologic basis (47, 48). Macrophages of the reticuloendothelial system appear to be central players in the sequestration and storage of HES *in vivo*. Tissue deposition in perivascular skin histiocytes was evident in most patients receiving HES. Also dermal infiltrates of foamy macrophages were observed upon histologic examination and HES deposition was observed in dermal macrophages of a patient with sudden hearing loss (46). Quality of life may be severely affected because of the long-lasting symptoms and the difficulty to treat.

At a reported rate of 0.058%, anaphylactoid, sometimes life-threatening reactions to HES are less common than to dextrans (42). Contrary to dextran-related anaphylaxis, the pathogenesis is not clear. Clinically relevant IgM or IgG antibodies could not be detected (49). In one case indirect evidence for an IgE-mediated reaction was shown by *in vitro* demonstration of specifically HES-activated basophils (50). Skin tests do not contribute to the diagnosis (51).

### Diagnostic procedures and allergologic investigations

In case of a suspected hypersensitivity reaction to an anticoagulant, treatment should be stopped. Heparin-induced thrombocytopenia II should be excluded by specific testing in specialized laboratories. In local skin reactions histology may help to differentiate cell-mediated

plaques from skin necrosis. In patients with skin necrosis or suspicion of HIT II skin tests are contraindicated, because even minute doses may exacerbate thrombocytopenia.

**In vivo tests**

Skin tests include prick, intradermal, and patch tests with heparins and hirudins. In a suspected immediate type hypersensitivity prick test with undiluted commercial drugs, and if negative, an intradermal test starting at a 1 : 1000 dilution should be performed first (Table 2). If negative, the intradermal tests should be repeated stepwise with lower dilutions. Typically undiluted intradermal heparins immediately cause irritant weal and flare because of some histamine-liberating activity. Therefore, tests should only be performed with a maximum 1 : 10 dilution. In cell-mediated hypersensitivity reactions, such as erythematous plaques and exanthemas, skin prick or intradermal tests with, e.g. 1 : 10 or undiluted heparins can be performed. Patch tests, possibly with tape stripings, are less sensitive but may be positive (6, 7, 52, 53).

Tested compounds should include UFHs (heparin sodium), LMWH, danaparoid, the pentasaccharide, fondaparinux, and hirudins (Table 2). Preservatives (chlorocresol, sulfites, etc.) should also be tested, if they are present in the trade products. Readings should be carried out at 20–30 min and at 24, 48 and 72 or 96 h, or even later, as very late reactions may be observed (6, 7, 52, 53).

Subcutaneous provocation tests are recommended to prove tolerance. They should be performed with increasing doses up to one daily defined dose in the abdominal wall and should be followed from day 1, up to days 5–7, as positive reactions may only occur after several days. Intravenous provocation tests may also be necessary to prove tolerance for emergency situations, such as thrombosis or pulmonary embolism. These should be performed by experienced and trained physicians in an appropriate surveillance setting only (54).

Patients with cell-mediated delayed hypersensitivity to LMWH may tolerate UF-heparin or the same product intravenously. This tolerance may be because of the lack of a particular protein to form an allergen, different antigen-presenting cells or a ‘compartment’ effect because of T-cell homing (6, 7, 52, 53). Therefore, in a life-threatening emergency situation such patients could receive UF-heparin intravenously. The most sensitive test for the diagnosis of sensitization is the intradermal test. Tolerance is best-proven with a subcutaneous or intravenous provocation test.

**In vitro tests**

*In vitro* tests, such as the lymphocyte transformation test, are rarely positive in patients with plaque reactions

Table 2. Diagnostic tests in hypersensitivity reactions to anticoagulants

Anticoagulant	Clinical reaction	Recommended test	Alternative test	Comments
Heparins	Plaque reactions, disseminated exanthema	Intradermal tests (dilution ≤ 1 : 10) Subcutaneous provocation test (undiluted)	Patch tests (undiluted)	Late reading (2–5 days), patch test less sensitive, provocation test for proof of tolerance with skin test-negative compound
	Urticaria, anaphylaxis Skin necrosis (HIT II)	Prick test (undiluted) Platelet count, anti-PF4-Ab assay	Intradermal test (dilution ≥ 1 : 100) Platelet aggregation test Serotonin release test (both not generally available) Intradermal (dilution ≥ 1 : 100) IgE antibodies (not generally available)	Reading 20–30 min Skin and provocation tests contraindicated
Hirudins	Urticaria, anaphylaxis	Prick test (undiluted)		Reading 20–30 min
Coumarins Dextrans	Necrosis Anaphylactoid reactions	Proteins C and S determination Antibody determination (IgG, IgM; not generally available)	None None	Skin tests and re-exposure contraindicated Skin tests not useful
Hydroxyethyl starch (HES)	Anaphylactoid reactions Delayed pruritus	None Skin biopsy	None None	Skin tests not useful Tissue deposits of HES in macrophages

HES, hydroxyethyl starch; HIT, heparin-induced thrombocytopenia; PF4, platelet factor 4; Ig, immunoglobulin.

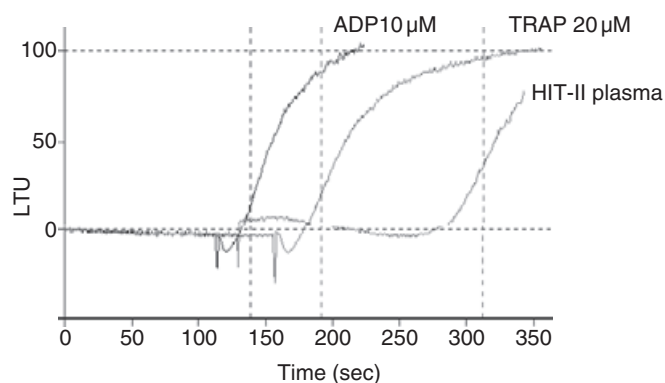


Figure 4. *In vitro*-induced platelet aggregation by heparin-induced thrombocytopenia II antibodies. Representative results of *in vitro*-induced platelet aggregation of normal platelets after addition of adenosine diphosphate (ADP, black curve) and thrombin-related activation peptide (TRAP, green curve) as obligate positive controls. Addition of test plasma with HIT II antibodies to normal platelets induces platelet aggregation after a latent phase (red curve) equal to the positive controls. Data are given as arbitrary light transmission units (LTU) in relation to time.

(55, 56). They are most often negative, possibly because of the immune modulating activity of heparins (57). In our experience also other tests, such as the sulfidoleukotriene release test detecting immediate hypersensitivity, do not give reproducible results and have a very low sensitivity.

For the diagnosis of HIT II platelet aggregation tests with low sensitivity (Fig. 4), the sensitive and specific serotonin release tests, heparin-induced platelet activation tests (HIPA), and detection of PF4-specific antibodies are available in specialized laboratories only.

In patients with coumarin necrosis proteins C and S deficiency should be excluded. In dextran-associated anaphylactic reactions dextran-reactive antibodies should be determined (43).

### Cross-reactivity and treatment alternatives

As heparins are important emergency drugs, e.g. in thromboembolism, the spectrum of the different types of hypersensitivity reactions should be known and should be adequately diagnosed as mentioned above (Table 2).

In cases of HIT II there may be broad cross-reactivity among the heparins. However, hirudins, danaparoid, and fondaparinux can be used as valid alternatives (23, 58).

In cell-mediated reactions to UFH and LMWH cross-reactivity may be extensive and even danaparoid and sodium pentosanpolysulfate (Fibrezym®; bene-Arzneimittel GmbH, Munich, Germany), both low-sulfated mucopolysaccharides, may show cross-reactivity to some extent (8). In one study, patients with delayed heparin allergy showed cross-reactions to danaparoid in 81.1% and to pentosanpolysulfate in 45.5% (6, 52, 53). The factor Xa inhibitor fondaparinux is an ultra-LMWH with a molecular weight of 1728 kDa. Its structure is an exact copy of a heparin pentasaccharide sequence. It is a new synthetic selective inhibitor of activated factor X and is effective in the prevention and treatment of deep vein thrombosis. After its introduction fondaparinux has become a recommended treatment alternative for patients with HIT II (25) or delayed plaques (59, 60). Although cross-reactivity appears to be rarer (8, 61), recently several cases with erythematous plaques to heparins and also to fondaparinux were reported (13). However, as mentioned above, even in patients with plaque reactions, intravenous UF-heparins are sometimes tolerated (62). So far, the high sulfatation of heparin molecules was thought to be crucial. These recent observations shed a new light on the discussion about antigenic structures of heparins.

In conclusion, a differentiated approach to patients with a suspected hypersensitivity reaction to an anticoagulant is mandatory. By applying adequate diagnostic tools and with correct interpretation usually a safe treatment alternative can be identified.

### References

- Hirsh J, O'Donnell M, Weitz JI. New anticoagulants. *Blood* 2005;**105**:453–463.
- Hirsh J, Raschke R. Heparin and low-molecular-weight heparin: the Seventh ACCP Conference on Antithrombotic and Thrombolytic Therapy. *Chest* 2004;**126**:188S–203S.
- Verstraete M. Pharmacotherapeutic aspects of unfractionated and low molecular weight heparins. *Drugs* 1990;**40**:498–530.
- Warkentin TE. An overview of the heparin-induced thrombocytopenia syndrome. *Semin Thromb Hemost* 2004;**30**:273–283.
- Wutschert R, Piletta P, Bounameaux H. Adverse skin reactions to low molecular weight heparins: frequency, management and prevention. *Drug Saf* 1999;**20**:515–525.
- Jappe U, Gollnick H. Allergy to heparin, heparinoids, and recombinant hirudin. Diagnostic and therapeutic alternatives. *Hautarzt* 1999;**50**:406–411.
- Bircher AJ. Allergische Reaktionen vom Spättyp auf Heparine. *Allergologie* 1993;**16**:268–274.
- Ludwig RJ, Schindewolf M, Alban S, Kaufmann R, Lindhoff-Last E, Boehncke WH. Molecular weight determines the frequency of delayed type hypersensitivity reactions to heparin and synthetic oligosaccharides. *Thromb Haemost* 2005;**94**:1265–1269.
- Bircher AJ. The differential diagnosis of heparin-induced skin lesions. *Br J Haematol* 1993;**85**:837.
- Jorg I, Fenyvesi T, Harenberg J. Anticoagulant-related skin reactions. *Expert Opin Drug Saf* 2002;**1**:287–294.

11. Harenberg J, Hoffmann U, Huhle G, Winkler M, Bayerl C. Cutaneous reactions to anticoagulants. Recognition and management. *Am J Clin Dermatol* 2001;**2**:69–75.
12. Bircher AJ, Flückiger R, Büchner S. Eczematous infiltrated plaques to subcutaneous heparin: a type IV allergic reaction. *Br J Dermatol* 1990;**123**:507–514.
13. Hohenstein E, Tsakiris D, Bircher AJ. Delayed-type hypersensitivity to the ultra-low-molecular-weight heparin fondaparinux. *Contact Dermatitis* 2004;**51**:149–151.
14. Häusermann P, Harr T, Bircher AJ. Baboon syndrome resulting from systemic drugs: is there strife between SDRIFE and allergic contact dermatitis syndrome? *Contact Dermatitis* 2004;**51**:297–310.
15. Bottio T, Pittarello G, Bonato R, Fagiolo U, Gerosa G. Life-threatening anaphylactic shock caused by porcine heparin intravenous infusion during mitral valve repair. *J Thorac Cardiovasc Surg* 2003;**126**:1194–1195.
16. Harr T, Scherer K, Tsakiris D, Bircher AJ. Immediate type hypersensitivity to several low molecular weight heparins and tolerance of unfractionated heparin and fondaparinux. *Swiss Med Wkly* 2005;**135**:0S17.
17. Bircher AJ, Itin P, Büchner S. Skin lesions, hypereosinophilia, and subcutaneous heparin. *Lancet* 1994;**343**:861.
18. Viillard JF, Neau D, Monlun E, Longy-Boursier M, Le Bras M. Hypereosinophilia associated with heparin: a case with a challenge test. *Thérapie* 1994;**49**:518.
19. Cines DB, Bussel JB, McMillan RB, Zehnder JL. Congenital and acquired thrombocytopenia. In: *Hematology 2004* ASH Educational Book. Broudy VC, Berliner N, Larson RA, Leung LL, editors. San Diego: The American Society of Hematology, 2004:309–406.
20. Handschin AE, Trentz O, Kock HJ, Wanner GA. Low molecular weight heparin-induced skin necrosis—a systematic review. *Langenbecks Arch Surg* 2005;**390**:249–254.
21. Hirsh J, Heddle N, Kelton JG. Treatment of heparin-induced thrombocytopenia: a critical review. *Arch Intern Med* 2004;**164**:361–369.
22. Amiral J, Meyer D. Heparin-dependent antigens in heparin-induced thrombocytopenia. In: Warkentin TE, Greinacher A, editors. *Heparin-induced thrombocytopenia*. New York-Basel: Marcel Dekker, Inc., 2004:165–177.
23. Warkentin TE. Heparin-induced thrombocytopenia: diagnosis and management. *Circulation* 2004;**110**:e454–458.
24. Chong BH, Magnani HN. Danaparoid for the treatment of heparin-induced thrombocytopenia. In: Warkentin TE, Greinacher A, editors. *Heparin-induced thrombocytopenia*. New York, Basel: Marcel Dekker, Inc., 2004:371–396.
25. Savi P, Chong BH, Greinacher A, Gruel Y, Kelton JG, Warkentin TE et al. Effect of fondaparinux on platelet activation in the presence of heparin-dependent antibodies: a blinded comparative multicenter study with unfractionated heparin. *Blood* 2005;**105**:139–144.
26. Greinacher A, Lubenow N, Eichler P. Anaphylactic and anaphylactoid reactions associated with lepirudin in patients with heparin-induced thrombocytopenia. *Circulation* 2003;**108**:2062–2065.
27. Greinacher A, Eichler P, Albrecht D, Strobel U, Potzsch B, Eriksson BI. Antihirudin antibodies following low-dose subcutaneous treatment with desirudin for thrombosis prophylaxis after hip-replacement surgery: incidence and clinical relevance. *Blood* 2003;**101**:2617–2619.
28. Bircher AJ, Czendlik C, Langauer Messmer S, Müller P, Howald H. Acute urticaria from subcutaneous recombinant hirudin. Evidence for an IgG-mediated hypersensitivity reaction. *J Allergy Clin Immunol* 1996;**98**:994–996.
29. Zollner TM, Gall H, Volpel H, Kaufmann R. Type IV allergy to natural hirudin confirmed by *in vitro* stimulation with recombinant hirudin. *Contact Dermatitis* 1996;**35**:59–60.
30. Smith KJ, Rosario-Collazo J, Skelton H. Delayed cutaneous hypersensitivity reactions to hirudin. *Arch Pathol Lab Med* 2001;**125**:1585–1587.
31. Jappe U, Reinhold D, Bonnekoh B. Arthus reaction to lepirudin, a new recombinant hirudin, and delayed-type hypersensitivity to several heparins and heparinoids, with tolerance to its intravenous administration. *Contact Dermatitis* 2002;**46**:29–32.
32. Chan YC, Valenti D, Mansfield AO, Stansby G. Warfarin induced skin necrosis. *Br J Surg* 2000;**87**:266–272.
33. Essex DW, Wynn SS, Jin DK. Late-onset warfarin-induced skin necrosis: case report and review of the literature. *Am J Hematol* 1998;**57**:233–237.
34. Antony SJ, Krick SK, Mehta PM. Unusual cutaneous adverse reaction to warfarin therapy. *South Med J* 1993;**86**:1413–1414.
35. Kruis-de Vries MH, Stricker BH, Coenraads PJ, Nater JP. Maculopapular rash due to coumarin derivatives. *Dermatologica* 1989;**178**:109–111.
36. Lebsack CS, Weibert RT. ‘Purple toes’ syndrome. *Postgrad Med* 1982;**71**:81–84.
37. Talmadge DB, Spyropoulos AC. Purple toes syndrome associated with warfarin therapy in a patient with antiphospholipid syndrome. *Pharmacotherapy* 2003;**23**:674–677.
38. Spyropoulos AC, Hayth KA, Jenkins P. Anticoagulation with anisindione in a patient with a warfarin-induced skin eruption. *Pharmacotherapy* 2003;**23**:533–536.
39. Ring J. Anaphylactoid reactions to intravenous solutions used for volume substitution. *Clin Rev Allergy* 1991;**9**:397–414.
40. Wang DY, Forslund C, Persson U, Wiholm BE. Drug-attributed anaphylaxis. *Pharmacoepidemiol Drug Saf* 1998;**7**:269–274.
41. van der Klauw MM, Wilson JH, Stricker BH. Drug-associated anaphylaxis: 20 years of reporting in The Netherlands (1974–1994) and review of the literature. *Clin Exp Allergy* 1996;**26**:1355–1363.
42. Lehmann G, Asskali F, Förster H. Schwerer Zwischenfall nach i.v.-Applikation von 10 ml (0,6 g) 6%igem Dextran60 bei einem gesunden Probanden. *Anaesthesist* 2002;**51**:820–824.
43. Bircher AJ, Hedin H, Berglund A. Probable grade IV dextran-induced anaphylactic reaction despite hapten inhibition. *J Allergy Clin Immunol* 1995;**95**:633–634.
44. Kraft D, Hedin H, Richter W, Scheiner O, Rumpold H, Devay ME. Immunoglobulin class and subclass distribution of dextran-reactive antibodies in human reactors and non reactors to clinical dextran. *Allergy* 1982;**37**:481–489.
45. Richter W, Hedin H, Kraft D, Messmer K. Anaphylactoid reactions after dextran. I. Immunology of the pathomechanism and the hapten inhibition. *Beitr Infusionther Klin Ernähr* 1981;**8**:54–65.
46. Bork K. Pruritus precipitated by hydroxyethyl starch: a review. *Br J Dermatol* 2005;**152**:3–12.
47. Boldt J. Hydroxyethyl starch—can the safety problems be ignored? *Wien Klin Wochenschr* 2004;**116**:640–641.
48. Wiedermann CJ. Hydroxyethyl starch—can the safety problems be ignored? *Wien Klin Wochenschr* 2004;**116**:583–594.
49. Dieterich HJ, Kraft D, Sirtl C, Laubenthal H, Schimetta W, Polz W et al. Hydroxyethyl starch antibodies in humans: incidence and clinical relevance. *Anesth Analg* 1998;**86**:1123–1126.



50. Ebo DG, Schuerwegh A, Stevens WJ. Anaphylaxis to starch. *Allergy* 2000;**55**:1098–1099.
51. Leynadier F, Wessel F. Skin tests for diagnosis of hypersensitivity to colloidal plasma substitutes. *Ann Fr Anesth Reanim* 2002;**21**:121s–122s.
52. Koch P. Delayed-type hypersensitivity skin reactions due to heparins and heparinoids. Tolerance of recombinant hirudins and of the new synthetic anticoagulant fondaparinux. *Contact Dermatitis* 2003;**49**:276–280.
53. Nicolie B, Bonneau JC, Le Sellin J, Gay G, Leclere JM, Drouet M. Delayed hypersensitivity to heparins and heparinoids. *Allerg Immunol (Paris)* 2002;**34**:47–50.
54. Aberer W, Bircher A, Romano A, Blanca M, Campi P, Fernandez J et al. Drug provocation testing in the diagnosis of drug hypersensitivity reactions: general considerations. *Allergy* 2003;**58**:854–863.
55. Bircher AJ. Diagnostic tests for delayed type-hypersensitivity reactions to heparins and safety of intravenous heparin. *Am J Contact Dermatitis* 1994;**5**:56–57.
56. Bircher AJ, Itin P, Tsakiris D, Surber C. Delayed hypersensitivity to one low-molecular-weight heparin with tolerance of other low-molecular-weight heparins. *Br J Dermatol* 1995;**132**:461–463.
57. Ji SL, Cui HF, Shi F, Chi YQ, Cao JC, Geng MY et al. Inhibitory effect of heparin-derived oligosaccharides on secretion of interleukin-4 and interleukin-5 from human peripheral blood T lymphocytes. *World J Gastroenterol* 2004;**10**:3490–3494.
58. Warkentin TE, Greinacher A. Heparin-induced thrombocytopenia: recognition, treatment, and prevention: the Seventh ACCP Conference on Antithrombotic and Thrombolytic Therapy. *Chest* 2004;**126**:311S–337S.
59. Maetzke J, Hinrichs R, Schneider LA, Scharffetter-Kochanek K. Unexpected delayed-type hypersensitivity skin reactions to the ultra-low-molecular-weight heparin fondaparinux. *Allergy* 2005;**60**:413–415.
60. Maetzke J, Hinrichs R, Staib G, Scharffetter-Kochanek K. Fondaparinux as a novel therapeutic alternative in a patient with heparin allergy. *Allergy* 2004;**59**:237–238.
61. Jappe U, Juschka U, Kuner N, Hausen BM, Krohn K. Fondaparinux: a suitable alternative in cases of delayed-type allergy to heparins and semisynthetic heparinoids? A study of 7 cases. *Contact Dermatitis* 2004;**51**:67–72.
62. Maroto-Iitani M, Higaki Y, Kawashima M. Cutaneous allergic reaction to heparins: subcutaneous but not intravenous provocation. *Contact Dermatitis* 2005;**52**:228–230.